

The “pancake flip”: Management of extreme internal curvature of the lower lateral cartilage

Steven Ross Mobley, MD

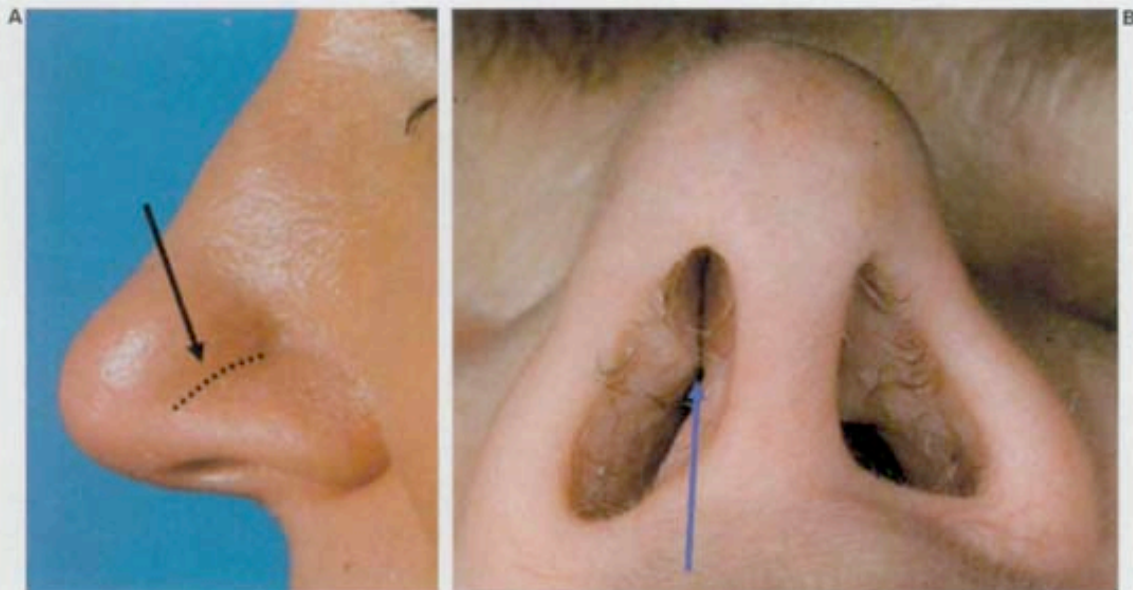


Figure 1. A: A prominent supra-alar depression should raise suspicion for a diagnosis of extreme internal curvature of the LLC. B: This diagnosis requires careful observation of the base view of the nose.

A less commonly observed and diagnosed cause of nasal obstruction is extreme internal curvature of the lower lateral cartilage (LLC), in which the natural horseshoe-shaped curvature of the LLC is so acute that the LLC itself curves into the nasal airway and thus contributes to the reduction of nasal airflow through the vestibule. The blockage is made even more severe when the cartilage makes contact with the septum. This diagnosis should be suspected in patients who have a prominent supra-alar depression (figure 1, A). The clinician must be certain to carefully observe the base view of the nose to make the diagnosis (figure 1, B). Insertion of a nasal speculum

will block visualization of this anatomic finding.

Correction is achieved through external-approach nasal surgery. The beginning point of the internal curvature is identified and marked, and the LLC is dissected (figure 2, A and B) completely free from the vestibular lining (figure 2, C). This LLC can be conceptualized as having two surfaces: the deep surface in contact with the vestibular lining and the superficial surface in contact with the nasal skin. In this technique, the cartilage is “pancake flipped,” so that the deep surface becomes the superficial surface. The LLC is sutured to the vestibular lining with through-and-through 6-0 PDS (polydioxanone) sutures (figure 2, D). This flip in

From the Division of Otolaryngology–Head and Neck Surgery, Department of Surgery, University of Utah School of Medicine, Salt Lake City.

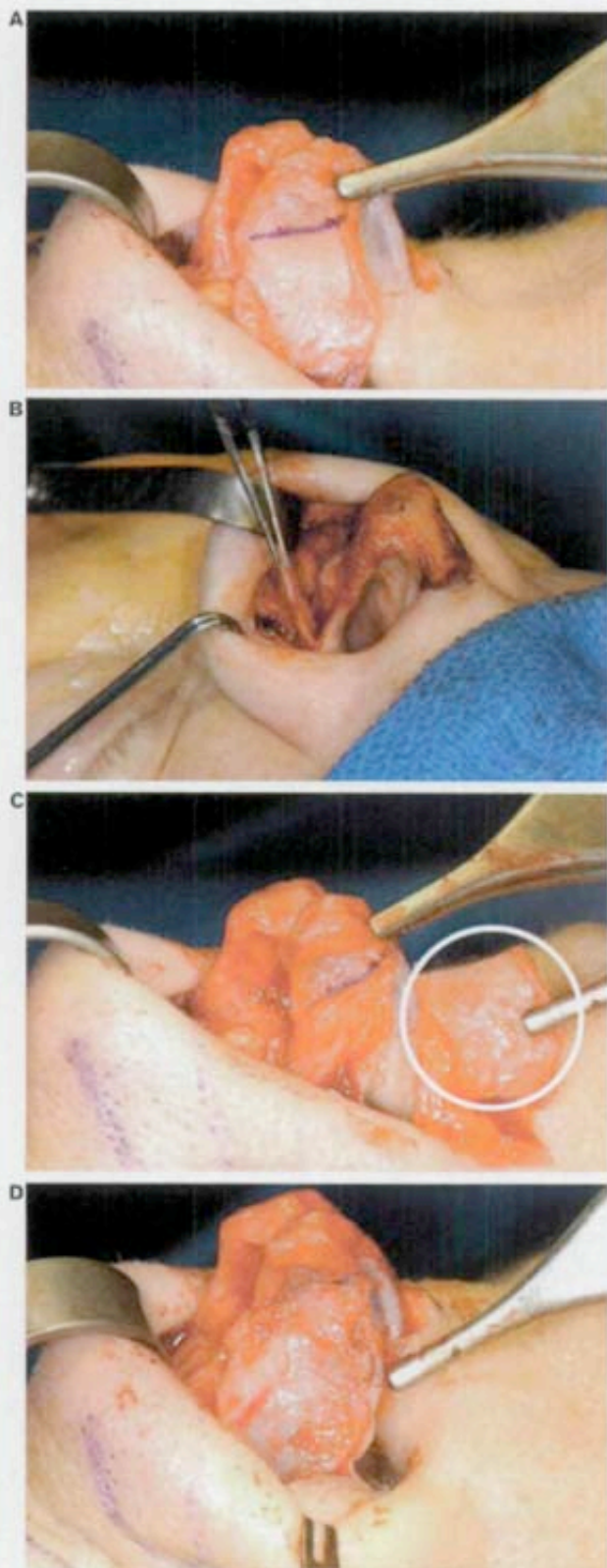


Figure 2. The LLC is dissected from the vestibular lining (A and B), then the cartilage (circled) is "pancake flipped" (C) and replaced back onto the vestibular lining, where it is sewn in place with through-and-through 6-0 PDS sutures (D).

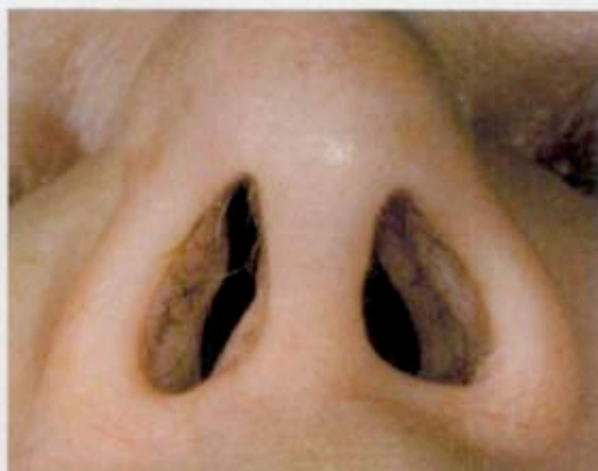

Figure 3. Postoperative photo shows that the procedure has significantly opened the nasal vestibule.

LLC orientation converts an airway-obstructing concavity into an airway-supporting convexity.

This procedure can dramatically open the nasal vestibule, as seen in this postoperative photo (figure 3).

A ONE DAY PRACTICAL COURSE:
BONE ANCHORED HEARING AIDS:
 A TECHNIQUE FOR EVERY ENT

Saturday, May 17, 2008
THE NEW YORK EYE & EAR INFIRMARY
 310 EAST 14TH STREET - NEW YORK CITY

For: ENT MDs, Residents in ENT and Audiologists
 Course to cover: Lecture/Didactics, Microsurgical Lab,
 Soft Tissue Work/Drilling & Insertion of Baha

Registration Info: Contact Melissa Willis, (646) 438-7858
 E-mail: mwillis@nyee.edu or visit www.childrenshearing.org

Course Faculty:

Christopher Linstorm, MD (Course Director)
 George Alexiades, MD
 Sujana Chandrasekhar, MD
 Ana Hae-ok Kim, MD

Course Sponsored by:

Baha®



Cochlear™
 Hear now. And always

Circle 113 on Reader Service Card

Copyright of ENT: Ear, Nose & Throat Journal is the property of Vendome Group LLC and its content may not be copied or emailed to multiple sites or posted to a listserv without the copyright holder's express written permission. However, users may print, download, or email articles for individual use.