

## Nasal bridge augmentation with a composite graft of autologous and alloplastic materials

Steven Ross Mobley, MD

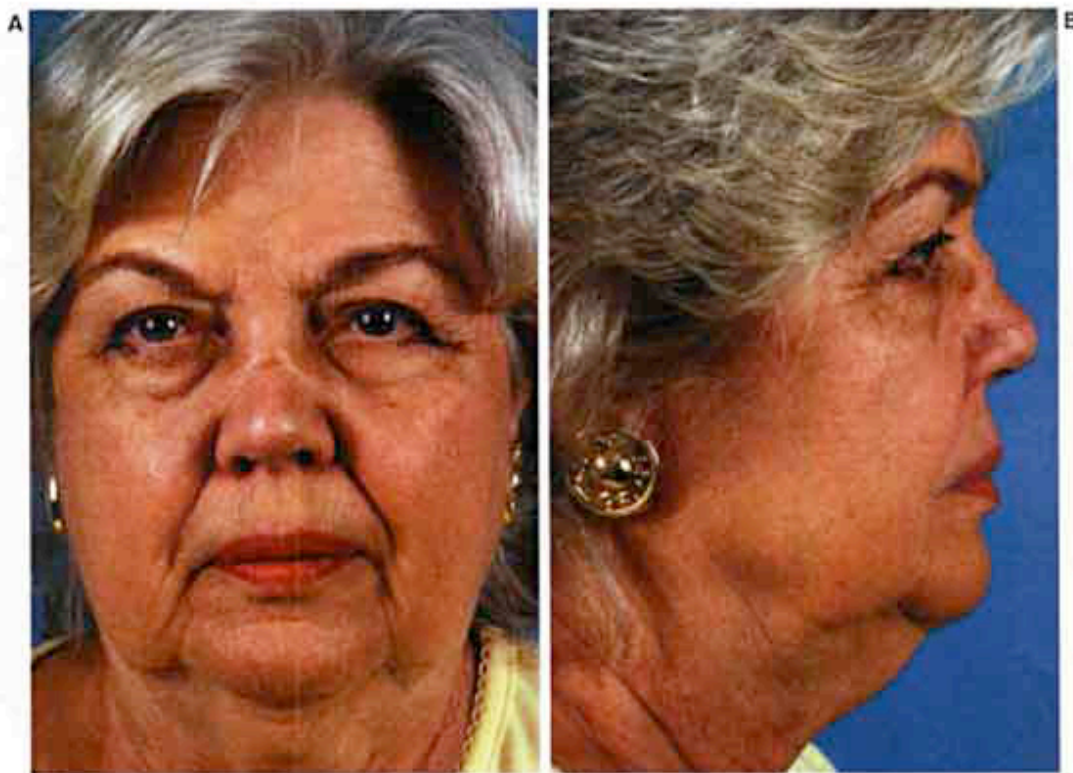

Figure 1. The patient presents with a saddle-nose deformity.

Augmentation of the nasal profile can be a reconstructive challenge for the rhinologic surgeon. Many surgeons appreciate the utility of auricular cartilage as an autologous graft material for nasal augmentation, but the natural concavities and convexities of harvested conchal bowl cartilage can make achieving a straight and even dorsum technically challenging. Other surgeons advocate the use of an alloplastic implant such as Gore-Tex (polytetrafluoroethylene), but there is strong support for the idea that the placement of alloplastic implants in the nose may increase the risk of infection over extended periods.

ENDURAGEN is a tough but flexible biomaterial made up of cross-linked porcine dermal collagen and its constituent

elastin fibers. Its use is indicated for tissue augmentation of the head and face, and it is commercially available in flat sheets. The author has developed a technique whereby the ENDURAGEN alloplast acts as a carrier for autologous auricular cartilage. When ENDURAGEN is used as a carrier, the bulk of the reconstruction material comes from the autologous cartilage, not the alloplast. The thin alloplast carrier helps to provide a smooth-appearing dorsum postoperatively by evening out the concavities and convexities that commonly occur in the natural surface shape of auricular cartilage.

A 73-year-old woman with a history of Wegener's granulomatosis presented with a saddle-nose deformity

From the Division of Otolaryngology-Head and Neck Surgery, Department of Surgery, University of Utah School of Medicine, Salt Lake City.

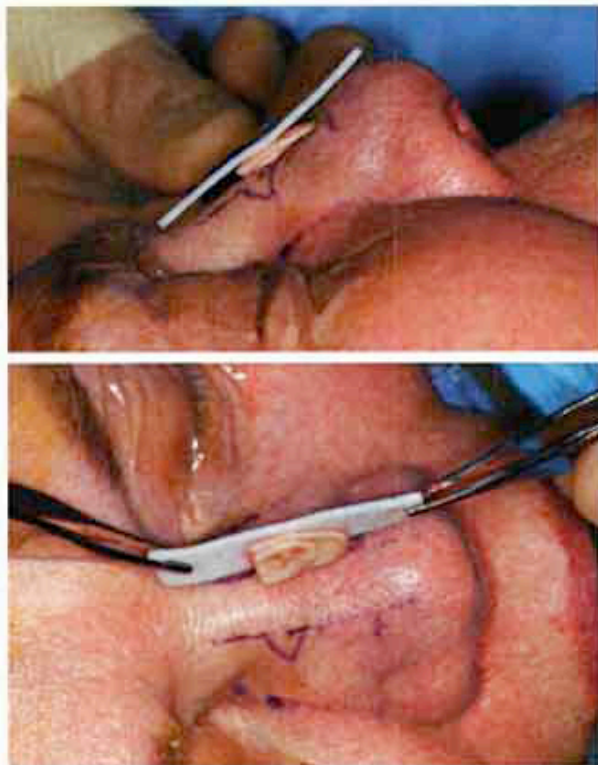


Figure 2. Harvested conchal bowl cartilage is cut into shape to fill in the deformity. Note how the ENDURAGen carrier helps to smooth out the natural concavities and convexities of the auricular cartilage.

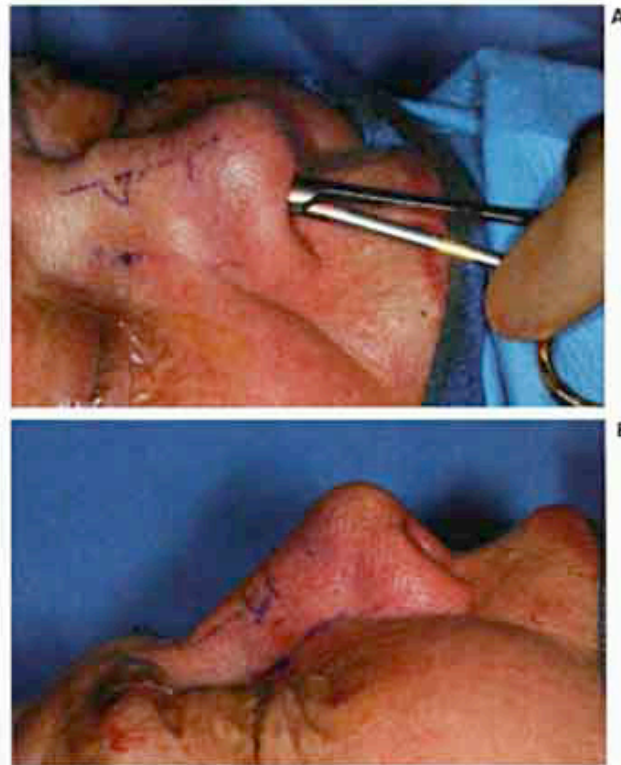

Figure 3. The composite graft is placed endonasally (A) and suture-fixed with transcutaneous 6-0 polypropylene sutures (B).

(figure 1). Upon evaluation, she was found to be a candidate for this technique. Harvested conchal bowl cartilage was cut into shape to fill in the deformity (figure 2). The ENDURAGen implant was sewn to this construct to act as a carrier and to provide smoother dorsal contour. The composite graft was placed endonasally (figure 3, A) and was suture-fixed with transcutaneous 6-0 polypropylene sutures (figure 3, B). Twelve months postoperatively, the cosmetic outcome was satisfactory (figure 4). If anything, the profile view revealed a bit of overcorrection, which is testament to the long-term effectiveness of this technique.

ENDURAGen porcine dermis is a helpful alloplastic material to aid in autologous cartilage augmentation of the nasal bridge. It is particularly helpful for surgeons who prefer to reconstruct mainly with autologous grafts that may present contour challenges, such as auricular cartilage

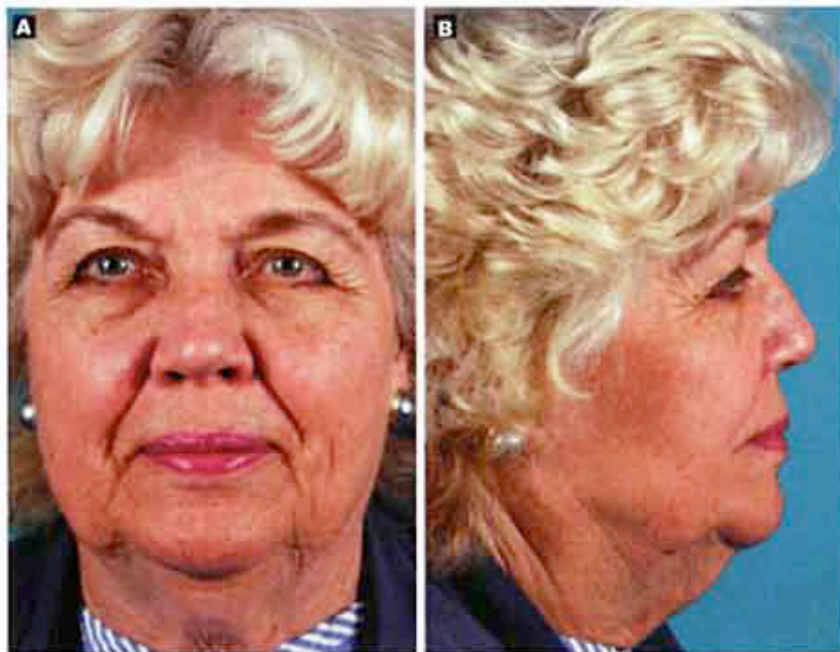

Figure 4. The cosmetic outcome 12 months postoperatively is satisfactory.

grafts. The ENDURAGen implant can serve as a biomaterial carrier to help provide a more natural dorsum contour.